

## ORIGINAL ARTICLE

## Focal irreversible electroporation for prostate cancer: functional outcomes and short-term oncological control

F Ting<sup>1,2,3</sup>, M Tran<sup>1,2,3</sup>, M Böhm<sup>2</sup>, A Siriwardana<sup>1,2,3</sup>, PJ Van Leeuwen<sup>1,2</sup>, A-M Haynes<sup>2</sup>, W Delprado<sup>4</sup>, R Shnier<sup>5</sup> and PD Stricker<sup>1,2,3</sup>

**BACKGROUND:** Current data on the use of irreversible electroporation (IRE) in the treatment of prostate cancer (PCa) is limited. We aim to evaluate the safety, short-term functional and oncological outcomes of focal IRE in low-intermediate risk PCa.

**METHODS:** Between February 2013 and May 2014, 32 consecutive men underwent IRE at a single centre. Patients with low-intermediate risk PCa who had not received previous PCa treatment were included for analysis. The tumour was ablated using 3–6 electrodes, ensuring a minimum 5-mm safety margin around the visible magnetic resonance imaging (MRI) lesion. Follow-up included recording Clavien complications, Expanded Prostate Cancer Index Composite (EPIC) questionnaires (baseline, 1.5, 3, 6 months), 6-month multi-parametric MRI (mp-MRI) and 7-month biopsy. Findings on mp-MRI and biopsy were sub-divided into in-field, adjacent or out-field of the treatment zone.

**RESULTS:** Twenty-five men were included for final analysis. Safety follow-up revealed one Clavien Grade 3 complication and five Grade 1 complications. Functional follow-up confirmed no significant change in American Urological Association urinary symptom score, sexual or bowel function. In-field, there were no suspicious findings on mp-MRI ( $n=24$ ) or biopsy ( $n=21$ ) in all patients. Adjacent to the treatment zone, five (21%) had suspicious findings on mp-MRI with four (19%) proving to be significant on biopsy. Out-field, there were two (8%) with suspicious findings on mp-MRI and one (5%) significant finding on biopsy. For the five patients with significant findings on follow-up biopsy, one is awaiting repeat IRE, one had radical prostatectomy and three remained on active surveillance.

**CONCLUSIONS:** In selected patients with low-intermediate risk PCa, focal IRE appears to be safe with minimal morbidity. There were no in-field recurrences and 76% of patients were histologically free of significant cancer at 8 months. Almost all recurrences were adjacent to the treatment zone, and this was addressed by widening the treatment margins.

*Prostate Cancer and Prostatic Diseases* (2016) **19**, 46–52; doi:10.1038/pcan.2015.47; published online 13 October 2015

## INTRODUCTION

Worldwide, the incidence of localised prostate cancer (PCa) is increasing.<sup>1</sup> Over-detection and treatment of low-risk PCa has become a concern<sup>2</sup> with the increasing use of PSA screening<sup>3</sup> and extended biopsy templates.<sup>4</sup>

Whole-gland treatment using surgery or radiotherapy has the potential to cause significant morbidity including erectile dysfunction, urinary incontinence and bowel toxicity.<sup>5–7</sup> As a result, focal therapy (FT) has emerged as a tissue-sparing treatment modality for selected men with low to intermediate volume, localised PCa with the advantage of reducing treatment morbidity owing to preservation of untreated prostate tissue and surrounding structures.<sup>8</sup> Currently available FT techniques include cryosurgery, high-intensity focal ultrasound, photodynamic therapy, radio-frequency ablation and laser-induced interstitial thermotherapy.

Irreversible electroporation (IRE) is an emerging FT modality that is Food and Drug Administration approved for the surgical ablation of soft tissue. Unlike other FT modalities, it relies on a non-thermal mechanism to induce cell death.<sup>9</sup> IRE uses needle electrodes placed in or around a targeted volume of tissue to deliver a series of brief direct-current electrical pulses with the intention of inducing a permanently porous cell membrane. This disrupts cellular homeostasis resulting in apoptosis.<sup>10</sup>

Current data on the use of IRE for treatment of PCa<sup>11,12</sup> are limited although a number of other studies are currently being undertaken.<sup>13–16</sup> Our primary objective is to provide short-term functional and oncological outcomes of IRE for PCa. Secondly, we aim to provide further data regarding the procedural aspects and safety of IRE. This will help to advance the evaluation of this technique in the management of PCa.

## MATERIALS AND METHODS

## Study population

From February 2013 to May 2014, the initial 32 consecutive patients underwent IRE at a single centre (St Vincent's Private Hospital, Sydney, Australia). Inclusion and exclusion criteria are described in Table 1.

## Informed consent and study approval

Informed consent was obtained from all patients, which entailed open disclosure of the procedure, potential risks and benefits. All men either refused or felt they were unsuitable for whole-gland therapy, accepted the need for ongoing surveillance and accepted the lack of long-term follow-up cancer data at the time of consent. The Human Research Ethics Committee at our facility granted institutional review board approval.

<sup>1</sup>St Vincent's Prostate Cancer Centre, Darlinghurst, NSW, Australia; <sup>2</sup>Garvan Institute of Medical Research/The Kinghorn Cancer Centre, Darlinghurst, NSW, Australia; <sup>3</sup>School of Medicine, University of New South Wales, Sydney, NSW, Australia; <sup>4</sup>Douglass Hanly Moir Pathology, Macquarie Park, NSW, Australia and <sup>5</sup>Southern Radiology, Randwick, NSW, Australia. Correspondence: Dr F Ting, Garvan Institute of Medical Research and the Kinghorn Cancer Centre, Level 6, The Kinghorn Cancer Centre, 370 Victoria Street, Darlinghurst, NSW 2010, Australia.

E-mail: francisting@gmail.com

Received 22 July 2015; accepted 25 August 2015; published online 13 October 2015

**Table 1.** Inclusion and exclusion criteria

<i>Inclusion criteria</i>
Signed informed consent by patient
Men who either refuse or feel unsuitable for whole-gland therapy
Men who have been counselled regarding IRE for prostate cancer and its relatively experimental nature
Age $\geq 40$ years
Visible lesion on mp-MRI with no evidence of ECE or SVI
Stage $\leq$ T2c on mp-MRI
Transperineal, TRUS or MRI-guided biopsies correlating with the visible lesion on mp-MRI
Gleason score $\leq 7$ on biopsy
Low-intermediate risk disease (D'Amico Criteria)
<i>Exclusion criteria</i>
Men who are unable to give informed consent
Men who are unable to undergo MRI (for example: incompatible metallic implant, claustrophobia)
Men with evidence of metastatic or nodal disease outside the prostate on mp-MRI or other imaging
Men who have had previous treatment for their prostate cancer, for example:
Irreversible electroporation
HIFU
Cryosurgery
Thermal/laser/microwave therapy
Men who have had previous radiation therapy to the pelvis
Men who have had androgen suppression/hormone treatment within the previous 12 months for their prostate cancer
Gleason score $\geq 8$ on biopsy

Abbreviations: ECE, extra-capsular extension; HIFU, high-intensity focussed ultrasound; IRE, irreversible electroporation; Mp-MRI, multi-parametric magnetic resonance imaging; SVI, seminal vesicle invasion; TRUS, trans-rectal ultrasound.

### Pre-operative work-up

Preoperatively all patients underwent, in sequential order: baseline PSA, multi-parametric magnetic resonance imaging (mp-MRI) and prostate biopsy.

Patients underwent trans-abdominal mp-MRI (T2-weighted imaging, diffusion-weighted imaging, dynamic contrast enhanced imaging) with a 3-Tesla magnet. All mp-MRIs were reported by expert sub-specialised radiologists who utilised the Standardised PIRADS (Prostate Imaging Reporting and Data System) comprising of a 5-point scale on which the presence of clinically significant cancer is 1–extremely unlikely, 2–unlikely, 3–equivocal, 4–likely or 5–extremely likely.<sup>17</sup> Eighteen regions of interest were indicated on a topographic map corresponding to biopsy template locations and were assigned a PIRADS score.

Histologic verification of suspicious areas was performed via transperineal template-guided mapping biopsy (TTMB), trans-rectal ultrasound-guided biopsy, MRI/trans-rectal ultrasound-guided biopsy fusion biopsy or MRI gantry biopsy.

### IRE methodology

IRE was performed as a day procedure, under general anaesthetic, with the patient placed in the lithotomy position. Intravenous gentamicin was administered at induction. A urinary catheter was placed, the bladder was emptied of urine and 50 ml of sterile water was instilled into the bladder as an electrically inert substitute.

IRE was performed using cognitive (manual MRI informed), transperineal grid-directed (5-mm sampling frame), trans-rectal ultrasound-guided biopsy-guided insertion of 18G NanoKnife electrodes (Angiodynamics, Queensbury, NY, USA). The placement of the electrodes aimed to ablate the lesion with an encapsulating octant or quadrant of the prostate, thus achieving a circumferential safety margin of at least 5 mm while still being mindful of nearby vital structures.

Technical considerations included spacing of the electrodes (required to be 10 mm to 20 mm apart), and a maximum electrode exposure length per needle of 20 mm. Thus, the number of electrodes required for each patient was dependent on the volume of tissue to be ablated.

After insertion of the electrodes, the distances between all electrodes were measured in the axial plane using trans-rectal ultrasound. The Nanoknife system was then programmed to deliver 90 pulses with pulse length set to 70  $\mu$ s. Treatment delivery was then automatically calculated by the system on the basis of the number of electrodes inserted, the respective distances between each electrode and the active electrode length to obtain an optimal electrical field of between 20 A and 40 A. This appears to be the optimal current range, which causes complete ablation within the target area while avoiding thermal damage.<sup>18</sup> Muscle paralysis was first administered, then 10 test pulses were delivered to verify the actual electrical field generated in the treatment zone. If the current was in the optimal range, the remaining 80 pulses were delivered; otherwise voltages were adjusted between electrodes that fell outside of the optimal range before delivering the remaining pulses.

The urethral catheter was removed on the day of procedure. However, if the patient had significant pre-operative lower urinary tract symptoms or if the treatment area abutted the urethra, the catheter was removed 3–5 days post treatment. Patients were discharged home on the day of procedure.

### Safety follow-up

Complications were recorded using the Clavien-Dindo classification system.<sup>19</sup>

### Functional follow-up

Functional outcomes were assessed using the validated Expanded Prostate Cancer Index Composite (EPIC) questionnaire,<sup>20</sup> which was completed at baseline, 6 weeks, 3 months and 6 months post-operatively. The outcomes extracted from the EPIC questionnaire included sexual, bowel, urinary, mental and physical short form summary scores, as well as pad-free continence rates, leak incontinence rates and erection quality.

### Oncological follow-up

Anatomical T2-weighted MRI was performed at 1 week to confirm a satisfactory ablation field. Mp-MRI at 6 months included T2-weighted imaging, diffusion-weighted imaging and dynamic contrast enhanced imaging and was performed to detect residual disease. Where logistically feasible all mp-MRIs were performed at our chosen facility where they were reported by a single experienced sub-specialised radiologist to assess for the likelihood of residual disease.

As there are not yet standardised guidelines on calculating PIRADS scores post FT, these were not calculated for treatment zone adjacent lesions on 6-month MRI. For infield and adjacent field lesions, if suspicion of residual cancer was raised by the radiologist in consultation with the treating urologist, this was recorded as a significant MRI finding. For outfield lesions, a PIRADS score of 4 or 5 was considered significant.

Histological follow-up with TTMB was performed with a 5 mm sampling frame in the peripheral zone and limited sampling of the transition zone from 18 template locations using a modified Barzell technique.<sup>21</sup> Additional cores were taken within and adjacent to the treatment zone. This was performed 7 months post procedure, and correlation with the mp-MRI was utilised to target regions of interests. Significant cancer on follow-up biopsy included Gleason score 6 with a core involvement of  $\geq 5$  mm and Gleason scores 7–10.

For interpretation and correlation of both imaging and biopsy results the prostate was divided into three zones. Infield was defined as the ablation zone, adjacent was defined as being within 10 mm of the ablated area, and outfield was defined as being outside these two zones. PSA monitoring was performed post procedure.

### Statistical analysis

Statistical analysis was performed using SPSS version 21.0 (IBM, Armonk, NY, USA). Wilcoxon's Signed Rank Test (two-tailed) and Wilcoxon's Rank Sum Test<sup>22</sup> was used to assess for statistically significant differences in paired continuous variables (EPIC questionnaire scores at baseline and 6 months) and unpaired continuous variables (age, PSA, lesion size) respectively. Statistical significance was set at  $P < 0.05$ .

## RESULTS

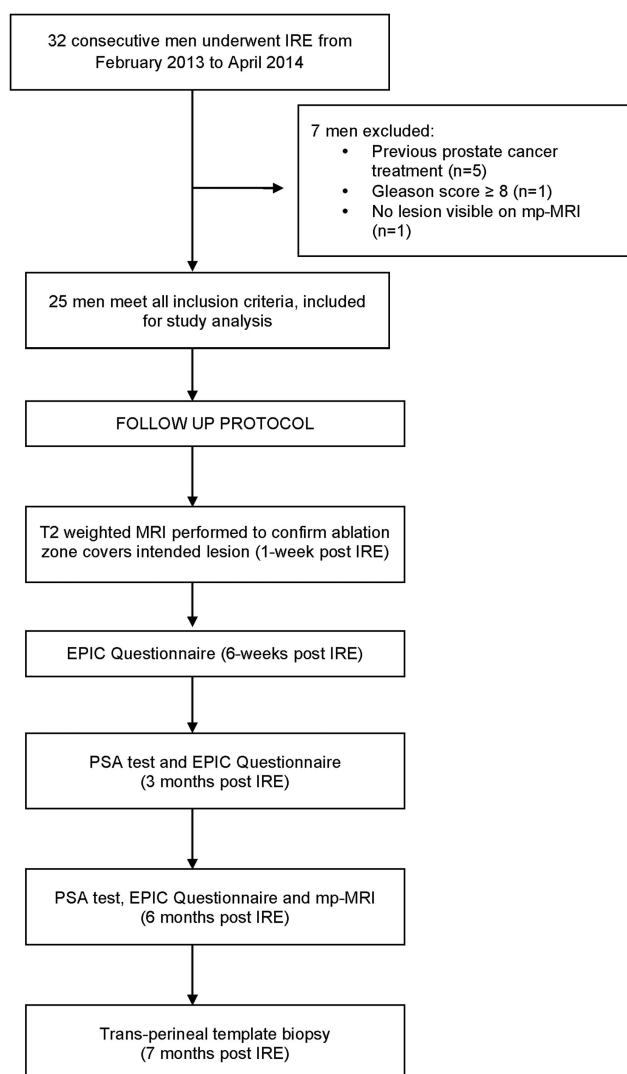
### Patient baseline data

Twenty-five patients were included for analysis after excluding men who had received previous PCa treatment ( $n=5$ ), men with Gleason score  $\geq 8$  ( $n=1$ ), and men with no lesion visible on mp-MRI ( $n=1$ ) (Figure 1). Baseline characteristics of the patients included for analysis are outlined in Table 2.

Mean age was 67 years and median pre-treatment PSA  $6.0 \text{ ng ml}^{-1}$  (IQR = 4.3–8.6). Eighteen men (72%) were worked-up with TTMB, three (12%) with trans-rectal ultrasound-guided biopsy, three (12%) with MRI fusion and one (4%) with MRI gantry biopsy of the prostate. According to D'Amico risk stratification, two patients (8%) were low risk and 23 (92%) were intermediate risk.

### Operative results

Operative IRE data are outlined in Table 3. A median of four probes were utilised per ablation, the range being three to six depending on lesion size and distribution. Median total time in the operating theatre was 64 min and median procedure time from beginning the insertion of needle electrodes to completion of ablation was 30 min.



**Figure 1.** Flowchart of patient selection and follow-up protocol. EPIC, Expanded Prostate Cancer Index Composite; IRE, irreversible electroporation; mp-MRI, multi-parametric magnetic resonance imaging.

**Oncological outcomes.** MRI at 1 week confirmed that the ablation zone covered the intended lesion in all patients except for one (24/25, 96%). This patient underwent repeat IRE; his subsequent 6-month MRI and 7-month biopsy were clear of significant disease.

Median PSA at 6 months median follow-up was  $2.2 \text{ ng ml}^{-1}$  (IQR 1.0–5.0) (Table 4). Twenty-four men (96%) underwent mp-MRI at 6 months and 21 men (84%) underwent TTMB at 7 months (Table 5).

For men who underwent follow-up biopsy, the ablated zone (infield) in 21/21 patients (100%) was histologically clear of

**Table 2.** Pre-operative data

Variable	Value
Age in years (median, IQR)	67 (60–71)
PSA (median; IQR)	6.0 (4.3–8.6)
PSA density ( $\text{ng ml}^{-1}$ ) per ml prostate (median; IQR)	0.15 (0.11–0.17)
<i>Clinical stage</i>	
T1C	11 (44%)
T2A	14 (56%)
T2B or greater	0 (0%)
<i>MRI measurements</i>	
Prostate volume on MRI in ml (median, IQR)	43 (32–60)
Maximum dimension of largest lesion on MRI in mm (mean, range)	12 (4–25)
<i>Number of lesions on MRI (median, IQR)</i>	
N = 1	19 (76%)
N = 2	3 (12%)
N = 3	3 (12%)
<i>Highest PIRADS score on MRI</i>	
PIRADS 2	0 (0%)
PIRADS 3	3 (12%)
PIRADS 4	9 (36%)
PIRADS 5	13 (52%)
<i>Transperineal biopsies (n = 18)</i>	
Number of cores taken (median; IQR)	29 (22–36)
Number of positive cores (median; IQR)	6 (2–7)
<i>TRUS biopsies (n = 3)</i>	
Number of cores taken (median; IQR)	12 (12–12.5)
Number of positive cores (median; IQR)	1 (1–1.5)
<i>MRI fusion/gantry biopsies (n = 4)</i>	
Number of cores taken (median; IQR)	6.5 (5–8)
Number of positive cores (median; IQR)	3 (2–4)
<i>Disease distribution on biopsy</i>	
Unilateral (n)	18 (72%)
Bilateral (n)	7 (28%)
<i>Gleason score</i>	
3+3	2 (8%)
3+4	15 (60%)
4+3	8 (32%)
4+4 or greater	0 (0%)
<i>D'Amico risk classification</i>	
Low	2 (8%)
Intermediate	23 (92%)
High	0

Abbreviations: IQR, interquartile range; MRI, magnetic resonance imaging; PIRADS, Prostate Imaging Reporting and Data System; TRUS, trans-rectal ultrasound.

**Table 3.** Perioperative data

Procedure parameter	Value
Number of probes used (mean, range)	4.6 (3–6)
Total time in theatre in min (median, IQR)	64 (60–81)
Procedure time in min (median, IQR)	30 (19–46)
Minimum voltage utilised during case (V) (mean, range)	1400 (900–2100)
Maximum voltage utilised during case (V) (mean, range)	2594 (1950–3000)
Minimum spacing between probes in mm (mean, range)	9 (6–12)
Maximum spacing between probes in mm (mean, range)	17 (13–20)
Probe exposure in mm (mean, range)	18 (15–25)
Catheterisation time in days (mean, range) <sup>a</sup>	1.8 (0–5) <sup>a</sup>
Hospital length of stay in nights (mean, range)	0.4 (0–5)

Abbreviation: IQR, interquartile range. <sup>a</sup>This figure has been calculated based on patients who did not have a TURP or BNI at the time of irreversible electroporation (*n* = 23).

**Table 4.** Follow-up data

<i>6-month follow-up parameter (n = 27)</i>	
6-month post procedure PSA (median, IQR)	2.2 (1.0–5.0)
<i>7-month biopsy parameter (n = 21)</i>	
Number of cores taken (median, IQR)	18 (14–27)
Number of patients with any positive cores	13/20 (72%)
Number of positive cores (median, IQR)	1 (0–4)
<i>Gleason score</i>	
Negative	8 (38%)
3+3	8 (38%)
3+4	3 (14%)
4+3	1 (5%)
4+4	1 (5%)
4+5	0 (0.0%)

Abbreviation: IQR, interquartile range.

disease. Overall, 16/21 men (76%) were histologically clear of significant disease and 8/21 (38%) men were histologically clear of any cancer at all on follow-up biopsy.

In the field adjacent to the ablation zone (adjacent field), 5/24 men (21%) had suspicious findings on 6-month mp-MRI. Four of these were proven to be significant on biopsy: two were at the anterior apex, one at the posterior apex and one at the left mid-gland postero-laterally.

In the field outside of the ablation zone (outfield), there were 2/24 patients (8%) with suspicious findings on 6-month mp-MRI; neither of these were significant on biopsy. On biopsy, outfield, one patient had a significant finding. This lesion was not detected on his 6-month mp-MRI and also was not detected pre-operatively as he had been worked-up with a targeted MRI fusion biopsy.

In total, 5/21 patients (24%) had significant disease on follow-up biopsy and their details are summarised in Supplementary Appendix 1. Three of these patients remain on active surveillance, one is awaiting repeat IRE and one underwent robot-assisted radical prostatectomy.

Currently, 23/25 (92%) patients remain on active surveillance. No patient has died or been switched over to systemic treatment. Disease characteristics of those undergoing successful initial IRE compared with those who had significant biopsy findings at

**Table 5.** Oncological results: recurrence rates

Oncological follow-up	Infield recurrences	Recurrences adjacent to treatment zone	Outfield recurrences
Magnetic resonance imaging ( <i>n</i> = 24)	0 (100%)	5/24 (21%)	2/24 (8%)
Biopsy ( <i>n</i> = 21)	0 (100%)	4/21 (19%)	1/21 (5%)

follow-up is set out in Table 6. There were no statistically significant differences in age, pre-operative PSA or lesion size on mp-MRI between the two groups.

**Functional outcomes.** Eighteen of 25 men (72%) completed EPIC questionnaires (Table 7). After 6 months follow-up, there was no significant change from baseline in urinary, sexual and bowel function as well as general physical and mental well-being summary scores.

#### Urinary function

Pad-free continence rates were 100, 94, 94 and 100% and leak-free continence rates were 67, 53, 65 and 67% at baseline, 6 weeks, 3 months and 6 months, respectively.

#### Erectile function

The proportion of men with erections sufficient for penetration were 44, 38, 47 and 56% at baseline, 6 weeks, 3 months and 6 months, respectively.

#### Health-related quality-of-life outcomes

General physical and mental health remained stable from baseline to 6 months post-operatively as indicated by short form 12 physical and mental health component scores (SF-12 PCS and SF-12 MCS, respectively in Table 7).

**Post-operative course and adverse events.** Twenty-two patients (88%) were treated as day procedure cases and three patients (12%) required admission post-operatively. One of these patients had a TURP and one had a bladder neck incision performed at the time of IRE.

No major intraoperative complications were encountered. Post-operatively there was one patient who had a non-ST elevation myocardial infarction (Clavien 3) and five patients (20%) who went into urinary retention (Clavien 1). Six patients (24%) reported intermittent haematuria at 6 weeks. No patients reported haematuria at 3 months.

For patients who did not have a TURP or bladder neck incision at the time of IRE (*n* = 23), the mean indwelling catheter time was 1.7 days. Fourteen out of these 23 patients (61%) had their catheter successfully removed on the day of procedure, with the remaining 9 patients having average catheter duration of 4.3 days.

## DISCUSSION

#### Oncological outcomes

A recent consensus meeting has stated that retreatment rates of  $\leq 20\%$  with FT and  $\leq 10\%$  with whole-gland therapy are clinically acceptable,<sup>23</sup> however only longer term follow-up will show whether our rates of  $< 10\%$  for both are robust. In addition, our short-term histological follow-up appears promising, with 76% of patients demonstrating histopathological absence of significant PCa at a median follow-up of 8 months. This is comparable to the 80.8% at 6 months follow-up biopsy reported in a recent series of 56 men undergoing high-intensity focal ultrasound focal ablation.<sup>24</sup> To our knowledge, there is no other data currently



**Table 6.** Comparison of pre-operative characteristics of patients free of significant disease compared with those with significant disease on follow-up biopsy

Pre-operative variable	No significant disease detected on follow-up (n = 20)	Significant disease on follow-up biopsy (n = 5)	P-value
Age (mean, range)	66 (55–86)	65 (57–73)	0.8
PSA (median, interquartile range)	5.3 (3.4–8.4)	6.1 (5.9–7.6)	0.4
Lesion size on MRI in mm (mean, range)	11 (4–20)	13 (5–25)	0.9
Bilateral distribution of disease on biopsy	4/20 (22.7%)	3/5 (60%)	
<i>Gleason score</i>			
3+3	2 (10%)	0 (0.0%)	
3+4	11 (55%)	4 (80%)	
4+3	7 (35%)	1 (20%)	
<i>D'Amico classification</i>			
Low	2 (10%)	0 (0.0%)	
Intermediate	18 (90%)	5 (100%)	

Abbreviation: MRI, magnetic resonance imaging.

**Table 7.** Quality-of-life data

EPIC questionnaire domain	Baseline (median, IQR)	6 weeks (median, IQR)	3 months (median, IQR)	6 months (median, IQR)	Difference from baseline at 6 months	
					Median	P-value
AUA urinary symptom score	8 (3–15)	8 (5–12)	7 (3–11)	5 (3–13)	–0.5	0.3
Urinary function summary score	90 (72–96)	75 (64–85)	93 (72–96)	94 (83–97)	0.0	0.6
Sexual function summary score	56 (51–75)	37 (29–63)	57 (31–65)	55 (34–69)	–0.7	0.4
Bowel function summary score	98 (93–100)	96 (93–98)	97 (93–100)	97 (93–100)	0.0	0.9
SF-12 physical component score	54 (43–56)	50 (43–56)	52 (43–56)	52 (43–56)	0	0.8
SF-12 mental component score	56 (47–58)	55 (47–60)	56 (54–59)	55 (50–60)	–0.2	0.2

Abbreviations: AUA, American Urological Association; EPIC, Expanded Prostate Cancer Index Composite; IQR, interquartile range.

published about short-term oncological outcomes post IRE for PCa.

Five patients (24%) had Gleason 7 or 8 PCa on follow-up biopsy, which is concerning but probably representative of our early learning curve. Four of these patients were found to have significant PCa in the region adjacent to the original ablation zone, suggesting that they could have been prevented if a wider margin was used. These four cases of significant adjacent field disease occurred within the first 12 patients treated in this series. Following this, the treatment margin was widened from 5 mm to 10 mm. As a result, the final 13 patients of this series were free of significant adjacent field disease on follow-up biopsy. A recent software-assisted, co-registration analysis comparing PCa lesion boundaries on MRI to histology specimens has, similarly, concluded that a 9 mm treatment margin is required around an MRI-visible lesion to consistently ensure treatment of the entire histologic tumour volume during FT.<sup>25</sup>

#### Functional outcomes

The functional outcomes of some of our IRE patients have previously been reported in collaboration with another centre.<sup>11</sup> In line with these initial findings, our functional outcomes to date are very promising with no significant decline in urinary, sexual or bowel function at 6 months. Similarly, general physical and mental well-being scores showed no significant decline at 6 months and remained quite stable throughout the follow-up period.

Robot-assisted radical prostatectomy has continence and potency rates at 12 months of 69–96%<sup>6</sup> and 54–90%,<sup>5</sup> respectively. Compared with this, a recent review of FT studies showed rates of pad-free continence of 95–100% and potency rates of 54–100%.<sup>8</sup> Our urinary functional outcomes appear to match this,

however, direct comparison of potency outcomes in our series is difficult due to the short follow-up and low baseline function of this patient cohort. Despite this, the fact that potency rates remained unchanged from baseline to 6 months is encouraging. In comparison, a recent series of high-intensity focal ultrasound reported leak-free, pad-free continence rates of 96% but the number of men with erections sufficient for penetration dropped by 25% at 6 months post treatment.<sup>24</sup> These results in comparison with high-intensity focal ultrasound may be a reflection of the inherent advantages attained through the mechanism of IRE.

In various animal studies IRE has been shown to preserve the tissue scaffold, sparing structures such as urethra, rectum, large blood vessels, neurovascular bundles and ductal systems.<sup>9,26,27</sup> These findings have been verified in canine studies where histopathology of prostates post IRE revealed that urethral structural integrity was preserved and nerves within neurovascular bundles appeared intact even when these structures were subject to direct ablation.<sup>9,28</sup> This may have important clinical implications in minimising adverse effects such as urinary symptoms and preserving potency.

#### Safety

Overall, toxicity of treatment was low, with the most common problems being post-operative haematuria (24%), dysuria (20%) and urinary retention (20%). No major intraoperative complications were observed.

There was one Grade 3 complication in our series, but this was not felt to be a direct effect of IRE itself, as no cardiac dysrhythmias were observed during IRE. This patient had a bladder neck incision at the time of IRE and antiplatelet medication was ceased 7 days pre-operatively. It is likely that this increased his risk of

post-operative myocardial infarction in the setting of a significantly ischaemic heart, which was exposed to the strain of a surgical procedure. He subsequently had an angiogram and drug-eluting stent to his left anterior descending coronary artery.

#### Utility of this study and future directions

Within the IDEAL framework<sup>29,30</sup> for introducing and assessing surgical innovation, this study explores the Stage 2a “Development” outcomes looking at refinement of technique as well as some of the Stage 2b “Exploration” outcomes, which include short-term oncological outcomes. Uptake of this treatment modality is still in the early stages and our reported data provides an initial analysis incorporating our learning curve to further inform other centres that are currently utilising this technique. It will also serve to inform future studies until larger trials are published, such as the Clinical Research Office of the Endourological Society Registry of IRE,<sup>15</sup> a multicentre, international trial, which is currently running and primarily aims to assess oncological control of disease at 1 and 5 years post IRE.

#### Limitations

The present study has several limitations. First, the sample size was small. Second, with a short follow-up duration it is difficult to make firm conclusions regarding the oncological outcome of this procedure in the intermediate-long term. Third, one patient underwent TURP and one underwent bladder neck incision at the time of IRE, which complicated interpretation of the safety and functional outcome data. Furthermore, there were considerable losses to follow-up. Functional follow-up was completed for 18 patients (72%) with the remaining seven (28%) either not completing or insufficiently completing EPIC Questionnaires. Oncological follow-up with both 6-month mp-MRI and 7-month biopsy was complete for 21 patients (84%), three patients (12%) underwent 6-month mp-MRI without 7-month biopsy and one patient (4%) did not complete either investigation due to cost. Of the other three patients not completing 7-month biopsy, two deferred the 7-month biopsy indefinitely and one patient refused due to side effects.

Finally, the pre-operative biopsy method was not standardised owing to logistical and patient-related reasons as these patients were often referred from other centres for consideration of IRE treatment. In addition, comparison of these pre-operative biopsies with the standardised TTMB performed post-operatively is a source of potential confounding. However, all patients received pre-operative mp-MRI, which has been shown to have a negative predictive value of 92–96%.<sup>31</sup> In most cases this should rule out significant PCa outside the biopsied areas, but in this series it resulted in one significant PCa lesion being missed on pre-operative work-up.

#### CONCLUSION

In conclusion, for selected patients with low-intermediate risk PCa, focal IRE appears to be safe with minimal morbidity and promising short-term functional outcomes.

To the best of our knowledge, this is the first study to look at the oncological outcomes of IRE for PCa. There were no infield recurrences, and 76% of patients were histologically free of significant cancer at a median follow-up of 8 months. Almost all recurrences were early in the series and adjacent to the treatment zone, and this was addressed by widening the treatment margins.

Formal prospective trials are currently running, and these analyses will help clarify the outcomes of IRE in PCa in the intermediate to long term.

#### CONFLICT OF INTEREST

The authors declare no conflict of interest.

#### ACKNOWLEDGEMENTS

Quoc Nguyen and Sarita Tiwari from Australian Prostate Cancer Research Centre-NSW (APCRC-NSW), IT applications group and CANSTO Database. This research is supported by The Department of Health and Ageing for its funding of the Australian Prostate Cancer Research Centre-NSW, The National Health and Medical Research Council, St Vincent's Prostate Cancer Centre and the RT Hall Trust.

#### REFERENCES

- 1 Siegel R, Ma J, Zou Z, Jemal A. Cancer statistics, 2014. *CA Cancer J Clin* 2014; **64**: 9.
- 2 Loeb S, Bjurlin MA, Nicholson J, Tammela TL, Penson DF, Carter HB *et al*. Overdiagnosis and overtreatment of prostate cancer. *Eur Urol* 2014; **65**: 1046.
- 3 Schroder FH, Hugosson J, Roobol MJ, Tammela TL, Ciatto S, Nelen V *et al*. Screening and prostate-cancer mortality in a randomized European study. *N Engl J Med* 2009; **360**: 1320.
- 4 Master VA, Chi T, Simko JP, Weinberg V, Carroll PR. The independent impact of extended pattern biopsy on prostate cancer stage migration. *J Urol* 2005; **174**: 1789.
- 5 Ficarra V, Novara G, Ahlering TE, Costello A, Eastham JA, Graefen M *et al*. Systematic review and meta-analysis of studies reporting potency rates after robot-assisted radical prostatectomy. *Eur Urol* 2012; **62**: 418.
- 6 Ficarra V, Novara G, Rosen RC, Artibani W, Carroll PR, Costello A *et al*. Systematic review and meta-analysis of studies reporting urinary continence recovery after robot-assisted radical prostatectomy. *Eur Urol* 2012; **62**: 405.
- 7 Sheets NC, Goldin GH, Meyer AM, Wu Y, Chang Y, Sturmer T *et al*. Intensity-modulated radiation therapy, proton therapy, or conformal radiation therapy and morbidity and disease control in localized prostate cancer. *JAMA* 2012; **307**: 1611.
- 8 Valerio M, Ahmed HU, Emberton M, Lawrentschuk N, Lazzeri M, Montironi R *et al*. The role of focal therapy in the management of localised prostate cancer: a systematic review. *Eur Urol* 2014; **66**: 732.
- 9 Onik G, Mikus P, Rubinsky B. Irreversible electroporation: implications for prostate ablation. *Technol Cancer Res Treat* 2007; **6**: 295.
- 10 Lee EW, Wong D, Prikhodko SV, Perez A, Tran C, Loh CT *et al*. Electronmicroscopic demonstration and evaluation of irreversible electroporation-induced nanopores on hepatocyte membranes. *J Vasc Interv Radiol* 2012; **23**: 107.
- 11 Valerio M, Stricker PD, Ahmed HU, Dickinson L, Ponsky L, Shnier R *et al*. Initial assessment of safety and clinical feasibility of irreversible electroporation in the focal treatment of prostate cancer. *Prostate Cancer Prostatic Dis* 2014; **17**: 343.
- 12 Neal RE 2nd, Millar JL, Kavnoudias H, Royce P, Rosenfeldt F, Pham A *et al*. In vivo characterization and numerical simulation of prostate properties for non-thermal irreversible electroporation ablation. *Prostate* 2014; **74**: 458.
- 13 van den Bos W, Muller BG, de la Rosette JJ. A randomized controlled trial on focal therapy for localized prostate carcinoma: hemiablation versus complete ablation with irreversible electroporation. *J Endourol* 2013; **27**: 262.
- 14 van den Bos W, de Bruin DM, Muller BG, Varkarakis IM, Karagiannis AA, Zondervan PJ *et al*. The safety and efficacy of irreversible electroporation for the ablation of prostate cancer: a multicentre prospective human in vivo pilot study protocol. *BMJ Open* 2014; **4**: e006382.
- 15 Rosette JD. Registry of irreversible electroporation for the ablation of prostate cancer with use of nanoknife device. *ClinicalTrials.gov: Clinical Research Office of the Endourological Society*, 2014.
- 16 Valerio M, Dickinson L, Ali A, Ramachandran N, Donaldson I, Freeman A *et al*. A prospective development study investigating focal irreversible electroporation in men with localised prostate cancer: nanoknife electroporation ablation trial (neat). *Contemp Clin Trials* 2014; **39**: 57.
- 17 Barentsz JO, Richenberg J, Clements R, Choyke P, Verma S, Villeirs G *et al*. Esur prostate Mr guidelines 2012. *Eur Radiol* 2012; **22**: 746.
- 18 Rubinsky J, Onik G, Mikus P, Rubinsky B. Optimal parameters for the destruction of prostate cancer using irreversible electroporation. *J Urol* 2008; **180**: 2668.
- 19 Dindo D, Demartines N, Clavien PA. Classification of surgical complications: a new proposal with evaluation in a cohort of 6336 patients and results of a survey. *Ann Surg* 2004; **240**: 205.
- 20 Wei JT, Dunn RL, Litwin MS, Sandler HM, Sanda MG. Development and validation of the expanded prostate cancer index composite (epic) for comprehensive assessment of health-related quality of life in men with prostate cancer. *Urology* 2000; **56**: 899.
- 21 Barzell WWIW, Andriole G. Transperineal template guided saturation biopsy of the prostate: rationale, indications and technique. *Urology Times* 2003; **31**: 41.
- 22 Kirkwood B. *Essential Medical Statistics*, 2nd edn. Blackwell Science: Mass Malden, 2003.

- 23 Donaldson IA, Alonzi R, Barratt D, Barret E, Berge V, Bott S *et al*. Focal therapy: patients, interventions, and outcomes-a report from a consensus meeting. *Eur Urol* 2015; **67**: 771.
- 24 Ahmed HU, Dickinson L, Charman S, Weir S, McCartan N, Hindley RG *et al*. Focal ablation targeted to the index lesion in multifocal localised prostate cancer: a prospective development study. *Eur Urol* 2015.
- 25 Julien Le N, Andrew BR, Arnauld V, Clément O, Fang-Ming D, Jonathan M *et al*. Image guided focal therapy of mri-visible prostate cancer: defining a 3d treatment margin based on MRI-histology co-registration analysis. *J Urol* 2015; **194**: 364–370.
- 26 Edd JF, Horowitz L, Davalos RV, Mir LM, Rubinsky B. In vivo results of a new focal tissue ablation technique: irreversible electroporation. *IEEE Trans Biomed Eng* 2006; **53**: 1409.
- 27 Maor E, Ivorra A, Leor J, Rubinsky B. The effect of irreversible electroporation on blood vessels. *Technol Cancer Res Treat* 2007; **6**: 307.
- 28 Tsivian M, Polascik TJ. Bilateral focal ablation of prostate tissue using low-energy direct current (ledc): a preclinical canine study. *BJU Int* 2013; **112**: 526.
- 29 McCulloch P, Altman DG, Campbell WB, Flum DR, Glasziou P, Marshall JC *et al*. No surgical innovation without evaluation: the ideal recommendations. *Lancet* 2009; **374**: 1105.
- 30 McCulloch P, Cook JA, Altman DG, Heneghan C, Diener MK. Ideal framework for surgical innovation 1: the idea and development stages. *BMJ* 2013; **346**: f3012.
- 31 Thompson JE, Moses D, Shnier R, Brenner P, Delprado W, Ponsky L *et al*. Multi-parametric magnetic resonance imaging guided diagnostic biopsy detects significant prostate cancer and could reduce unnecessary biopsies and over detection: a prospective study. *J Urol* 2014; **192**: 67.

Supplementary Information accompanies the paper on the Prostate Cancer and Prostatic Diseases website (<http://www.nature.com/pcan>)