

See discussions, stats, and author profiles for this publication at: <http://www.researchgate.net/publication/260482911>

# Prolonged venovenous extracorporeal membrane oxygenation without anticoagulation: a case of Goodpasture syndrome-related pulmonary haemorrhage.

**ARTICLE** *in* CRITICAL CARE AND RESUSCITATION: JOURNAL OF THE AUSTRALASIAN ACADEMY OF CRITICAL CARE MEDICINE · MARCH 2014

Impact Factor: 2.15 · Source: PubMed

---

CITATION

1

---

DOWNLOADS

29

---

VIEWS

112

## 3 AUTHORS, INCLUDING:



**Hergen Buscher**

St. Vincent's Hospital Sydney

32 PUBLICATIONS 113 CITATIONS

SEE PROFILE



**Priya Nair**

St. Vincent's Hospital Sydney

27 PUBLICATIONS 511 CITATIONS

SEE PROFILE

# Prolonged venovenous extracorporeal membrane oxygenation without anticoagulation: a case of Goodpasture syndrome-related pulmonary haemorrhage

David G Herbert, Hergen Buscher and Priya Nair

Extracorporeal membrane oxygenation (ECMO) for acute lung injury (ALI) and acute respiratory distress syndrome (ARDS) is an increasingly used modality internationally and in Australia and New Zealand.<sup>1</sup> Its implementation is limited by a number of factors, among which is the requirement for therapeutic anticoagulation to prevent thrombosis caused by activation of the coagulation pathway within the extracorporeal circuit.<sup>2</sup> Small numbers of cases in heterogeneous patient groups mean that ECMO research is necessarily reliant on retrospective and case-based analysis, and its clinical implementation is based on local protocols. Evidence regarding anticoagulation from prospective trials is absent. Guidelines include the inability to use systemic anticoagulation as an absolute contraindication to ECMO implementation,<sup>2</sup> effectively excluding patients with major bleeding risks. In this paper we report the use of venovenous (VV)-ECMO without systemic anticoagulation for 25 days (20 days consecutively). The patient had a total ECMO period of 26 days and suffered no adverse thrombotic events.

## Clinical record

A 16-year-old New Caledonian male presented to his local hospital after 8 days of worsening dyspnoea and fatigue with 3 days of haemoptysis. The patient was otherwise well with no known medical conditions and comorbidities, medications or allergies. He had no recent sick contacts; however, a current local outbreak of leptospirosis was noted on admission.

The patient was admitted to a local intensive care unit on broad spectrum antibiotics and non-invasive ventilation, requiring intubation and ventilation shortly thereafter for hypoxaemic respiratory failure. Ventilation was difficult, with a positive end-expiratory pressure (PEEP) of 18 cm H<sub>2</sub>O, a plateau pressure of 32 cm H<sub>2</sub>O, a P/F ratio of 56 with minute volumes of about 3 L, and a partial pressure of arterial CO<sub>2</sub> of 52 mmHg (reference interval [RI], 32–45 mmHg). His condition continued to decline with worsening haemoptysis, requiring multiple transfusions. At this stage the decision was made to organise VV-ECMO retrieval to Australia.

## ABSTRACT

We present a 16-year-old male with severe acute respiratory and renal failure as a result of Goodpasture syndrome, requiring venovenous extracorporeal membrane oxygenation (VV-ECMO) for pulmonary haemorrhage. The patient received no systemic anticoagulation for 25 of 26 ECMO days (20 days consecutively) and suffered no coagulation-related adverse events. The patient had a subtherapeutic anticoagulation profile according to recommended ECMO guidelines during most of this time. The patient made a full recovery without respiratory compromise, ECMO circuit failure, thrombotic events or the need for ongoing haemodialysis.

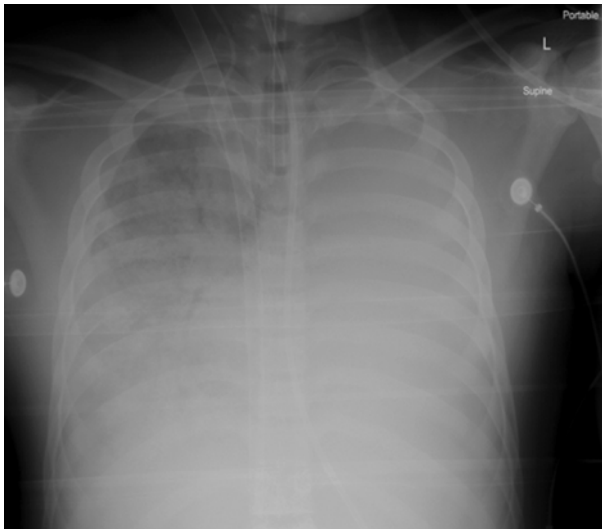
Crit Care Resusc 2014; 16: 69–72

A single 31 Fr double-lumen ECMO cannula (Avalon) was inserted into the right internal jugular vein. A single dose of heparin (10 000 units) was given at the time of insertion. Oxygenation improved immediately, and the patient was transferred to an ECMO centre in Sydney, Australia, by air ambulance (1970 km). The transfer was uneventful with the ECMO centrifugal pump (Cardiohelp; Maquet) running at 3200 rpm maintaining 3.6–4.0 L/min blood flows with fresh gas flows of 7 L/min.

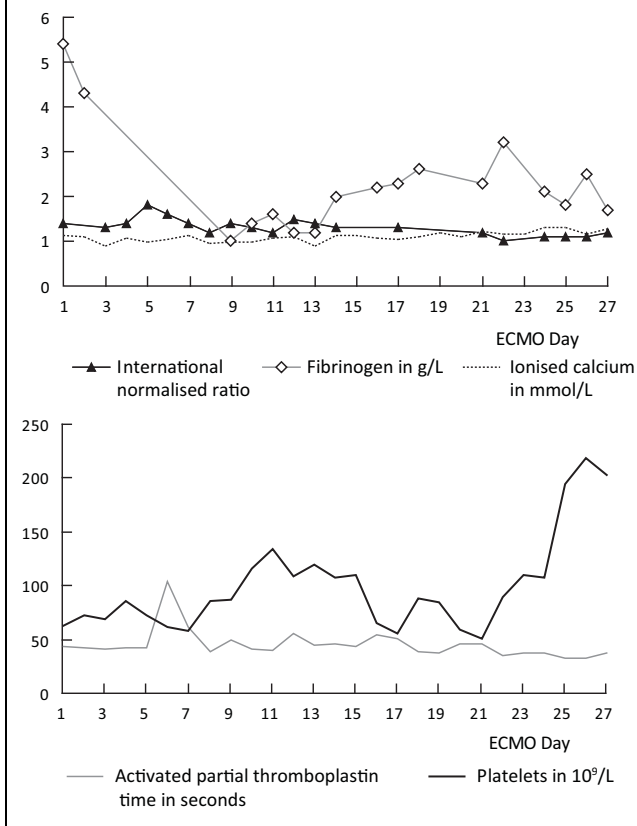
After arrival, the ECMO circuit was initially run without anticoagulation because of ongoing pulmonary haemorrhage (Figure 1). On Day 5, a conservative dose of systemic heparin was commenced, resulting in a rapidly responsive activated partial thromboplastin time (APTT) (peaking at 104 seconds) and increased pulmonary haemorrhage. Heparin was ceased and not recommenced during the ECMO run.

Severe respiratory failure continued with minute volumes of less than 0.4 L on lung protective ventilation. Renal function also declined from a normal baseline to a creatinine level of 502 µmol/L (RI, 60–120 µmol/L), urea 17.7 mmol/L (RI, 3.0–8.5 mmol/L) and continuous venovenous haemodiafiltration (CVVHDF) was commenced via the ECMO circuit (ECMO Day 3).

**Figure 1. Chest x-ray showing diffuse pulmonary haemorrhage**



**Figure 2. Coagulation profile during the use of venovenous extracorporeal membrane oxygenation**



Following positive results for serum antglomerular basement membrane (anti-GBM) antibodies (titre, >200 U/mL), positive renal biopsy, and negative infective, autoimmune and vasculitic studies, Goodpasture disease was diagnosed, and a treatment regimen of steroids, cyclophosphamide and plasmapheresis was commenced with supplemental intravenous immunoglobulin infusions for hypogammaglobulinaemia. During the course of admission, 23 plasmapheresis exchanges were performed, 16 while on ECMO (between Day 5 and Day 26). Each plasmapheresis exchange contains about 40–80 mL of acid citrate dextrose, which can cause systemic anticoagulant effects; however, the patient's APTT, international normalised ratio (INR), platelets and ionised calcium levels remained steady during these exchanges. Coagulation status was monitored with APTT, prothrombin time, INR, fibrinogen and platelet levels throughout admission, and Doppler ultrasound studies during admission were negative for deep vein thrombosis. Details of coagulation status during ECMO are displayed in Figure 2.

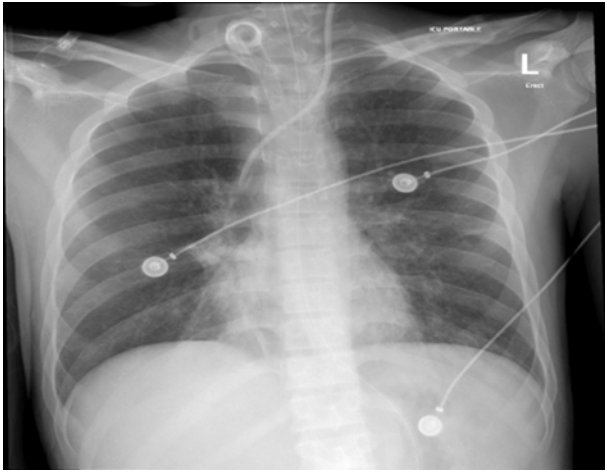
In addition to respiratory and renal failure, nosocomial infections that developed during admission included vancomycin resistant *Enterococcus* (VRE) colonisation, oral herpes simplex virus (HSV), a yeast urinary infection and *Streptococcus mitis* bacteraemia. After a prolonged course of immunosuppression including plasmapheresis for Goodpasture syndrome, pulmonary function improved, enabling weaning off ECMO on Day 26 (Figure 3).

Weaning off the ventilator was prolonged, and a temporary tracheostomy was inserted on Day 33. CVVHDF was bridged to intermittent haemodialysis along with intermittent plasmapheresis until the anti-GBM antibody became negative on Day 48. Renal function improved thereafter and dialysis was ceased. After a 68-day admission, the patient was discharged back to New Caledonia with normal respiratory function and no ongoing haemodialysis requirement.

## Discussion

Anticoagulation is generally considered an essential part of ECMO circuit management and the potential for serious thromboembolic events is well established.<sup>1,3</sup> However, the use of systemic anticoagulation carries significant risks, including new and increased bleeding as well as the potential for heparin-induced thrombocytopenia where heparin is used.<sup>4</sup> The risk of major haemorrhage is also well established in ECMO use, and in the latest data from the Extracorporeal Life Support Organization from 2012, there were 313 pulmonary haemorrhage events reported (8.1% of reported events) with an associated survival of 36%.<sup>1</sup>

**Figure 3. Chest x-ray after extracorporeal membrane oxygenation decannulation and tracheostomy insertion**



Severe ARDS and acute lung injury, particularly severe pulmonary haemorrhage, carry significant mortality.<sup>5</sup> Although ECMO support has the potential to improve outcomes in severe ARDS, there are only a few published reports of its use in patients with severe bleeding.<sup>6-9</sup> The reluctance to institute ECMO in patients at risk of haemorrhage is due to concerns about using systemic anticoagulation in these patients. Anticoagulant use in ECMO is predicated on concerns about the ECMO circuit's artificial surfaces activating clotting cascades.<sup>10</sup> In order to minimise this pro-coagulant effect, modern ECMO circuits are coated with heparin and contain miniaturised pumps and oxygenators. Although systemic anticoagulation during ECMO remains standard of care,<sup>11</sup> these improvements may allow a more conservative approach to anticoagulation.

In a study of 68 patients requiring ECMO support in Australia and New Zealand during the 2009 H1N1 influenza pandemic, despite good outcomes overall, haemorrhagic complications occurred in 37 patients (54%), including intracerebral haemorrhage in six patients.<sup>12</sup> Further, blood transfusion and blood product use was common in these patients (median amount of blood administered, 1880 mL; interquartile range, 904–3750 mL). At the same time, sub-optimal anticoagulation could result in thrombotic complications (although these are difficult to detect clinically, unless clotting of the ECMO circuit occurs, which was not seen in this population). This suggests that the anticoagulant protocols used may be excessive, and strategies that employ less anticoagulation may be safer.<sup>6</sup> In this case report we describe a patient with severe pulmonary haemorrhage complicating the use of ECMO. There are two previous case reports of the use of ECMO in Goodpasture

disease. In both instances anticoagulation was maintained throughout ECMO support. In one of these cases, a 49-year-old man died after 3 days on ECMO due to severe pulmonary haemorrhage;<sup>13</sup> and in the other case, a 9-year-old girl recovered normal respiratory function after 6 days of ECMO with systemic heparin (dose, 100 U/kg).<sup>14</sup> As in our case, this patient underwent plasmapheresis as part of her treatment regimen. Plasmapheresis is a modality that has potential effects on coagulation. In the context of ECMO and coagulation status, it bears some consideration; however, from a review of the literature, it is unclear what changes can be expected in ECMO with plasmapheresis, with much of the relevant research being only indirectly applicable.<sup>15</sup> Although plasmapheresis may alter coagulation, requiring careful monitoring,<sup>16</sup> in our case, coagulation status and other markers such as ionised calcium remained stable during plasmapheresis (Figure 2).

A recent case report describes warfarin-induced diffuse alveolar haemorrhage (DAH), which required VV-ECMO for 5 days and where no systemic anticoagulation was used.<sup>8</sup> The authors describe aggressive reversal of anticoagulation and an APPT aim of 22–31 seconds throughout ECMO use. ECMO support in the context of major trauma is an area where withholding anticoagulation would be of great interest. Two recent articles describe a total of 13 patients with significant haemorrhage who received VV-ECMO without systemic anticoagulation for up to 5 days.<sup>6,9</sup> Muellenbach et al<sup>9</sup> describe three cases where severe haemorrhage was present during ECMO implementation, and the circuits were run without systemic anticoagulation for a variable length of time. The longest of these was 5 days, and this patient suffered no thrombotic complications. Although all three patients made a good recovery, one of these patients developed vena caval thrombosis, which was treated with systemic anticoagulation and resolved before discharge. Arlt et al<sup>6</sup> describe a series of 10 severe trauma patients managed with heparin-free VV-ECMO in the initial phase of ECMO without thromboembolic events, thromboses or compromised ECMO circuit function. In this study, there was a mortality of 40%; however, only one death was related to haemorrhage. These articles support the consideration of ECMO use in severe trauma patients who would otherwise be considered at too high risk of major haemorrhage for ECMO. Lappa et al<sup>7</sup> describe weaning from VV-ECMO without systemic anticoagulation in a patient with severe ARDS who developed life-threatening femoral artery haemorrhage.

Although there is increasing interest in anticoagulant-free VV-ECMO, the longest previously reported case of ECMO without systemic anticoagulation was 5 days.<sup>8,9</sup> Other reports describe ECMO without the use of systemic anticoagulation in the initial phase only<sup>6</sup> or during weaning before

decannulation.<sup>7</sup> In our case, VV-ECMO was run uneventfully without systemic anticoagulation for more than 25 days with a normal to mildly deranged coagulation profile throughout. The platelet count and fibrinogen level remained below normal throughout prolonged periods of treatment, which reflects consumption by ongoing pulmonary haemorrhage and extracorporeal circulation. It remains unclear whether heparin treatment would have avoided this in part. We opted to apply a conservative approach in replacing these given the significant risk of thromboembolic events.

Case reports of severe haemorrhagic complications during anticoagulation in ECMO highlight the need for cautious treatment decisions in the use and timing of anticoagulation in these patients.<sup>17</sup> Although the evidence for anticoagulant-free VV-ECMO in haemorrhagic conditions is far from extensive, no previous case reports have demonstrated the safety of such prolonged use of anticoagulant-free VV-ECMO.

In contrast, during peripheral venoarterial ECMO, the presence of an arterial cannula, a narrow bore backflow cannula to the lower limb, as well as potentially low blood flow within the cardiac chambers, suggest that this approach may not be as safe in these patients.

This case demonstrates favourable clinical outcomes, without thromboembolic complications, in a patient with pulmonary haemorrhage on VV-ECMO support without systemic anticoagulation for a prolonged period. Future prospective trials should aim to identify the lowest safe level of anticoagulation in various ECMO configurations and indications. Goal-directed protocols guided by point-of-care testing (such as thromboelastometry and platelet function test) to manage haemorrhagic complications, potentially including cessation of anticoagulation, might prove to be useful.

## Competing interests

None declared.

## Author details

David G Herbert, Registrar<sup>1</sup>

Hergen Buscher, Staff Specialist<sup>1,2</sup>

Priya Nair, Staff Specialist<sup>1,2,3</sup>

1 Intensive Care Unit, St Vincent's Hospital, Sydney, NSW, Australia.

2 University of New South Wales, Sydney, NSW, Australia.

3 Garvan Institute for Medical Research, Sydney, NSW, Australia.

**Correspondence:** daveyherby@gmail.com

## References

- 1 Extracorporeal Life Support Organization. Welcome! <http://www.elsonet.org/> (accessed May 2013).
- 2 Oliver WC. Anticoagulation and coagulation management for ECMO. *Semin Cardiothorac Vasc Anesth* 2009; 13: 154-75.
- 3 Chen JM, Richmond ME, Charette K, et al. A decade of pediatric mechanical circulatory support before and after cardiac transplantation. *J Thorac Cardiovasc Surg* 2012; 143: 344-51.
- 4 Pollak U, Yacobovich J, Tamary H, et al. Heparin-induced thrombocytopenia and extracorporeal membrane oxygenation: a case report and review of the literature. *J Extra Corpor Technol* 2011; 43: 5-12.
- 5 Bersten AD, Edibam C, Hunt T, Moran J; Australian and New Zealand Intensive Care Society Clinical Trials Group. Incidence and mortality of acute lung injury and the acute respiratory distress syndrome in three Australian states. *Am J Respir Crit Care Med* 2002; 165: 443-8.
- 6 Arlt M, Philipp A, Voelkel S, et al. Extracorporeal membrane oxygenation in severe trauma patients with bleeding shock. *Resuscitation* 2010; 81: 804-9.
- 7 Lappa A, Donfrancesco S, Contento C, et al. Weaning from venovenous extracorporeal membrane oxygenation without anticoagulation: is it possible? *Ann Thorac Surg* 2012; 94: e1-3.
- 8 Lee JH, Kim SW. Successful management of warfarin-exacerbated diffuse alveolar hemorrhage using an extracorporeal membrane oxygenation. *Multidiscip Respir Med* 2013; 8: 16.
- 9 Muellenbach RM, Kredel M, Kunze E, et al. Prolonged heparin-free extracorporeal membrane oxygenation in multiple injured acute respiratory distress syndrome patients with traumatic brain injury. *J Trauma Acute Care Surg* 2012; 72: 1444-7.
- 10 Müller T, Philipp A, Luchner A, et al. A new miniaturized system for extracorporeal membrane oxygenation in adult respiratory failure. *Crit Care* 2009; 13: R205.
- 11 Kopp R, Bensberg R, Henzler D, et al. Hemocompatibility of miniaturized extracorporeal membrane oxygenation and a pumpless interventional lung assist in experimental lung injury. *Artif Organs* 2010; 34: 13-21.
- 12 Australia and New Zealand Extracorporeal Membrane Oxygenation Influenza Investigators. Extracorporeal membrane oxygenation for 2009 influenza A(H1N1) acute respiratory distress syndrome. *JAMA* 2009; 302: 1888-95.
- 13 Daimon S, Umeda T, Michishita I, et al. Goodpasture's-like syndrome and effect of extracorporeal membrane oxygenator support. *Intern Med* 1994; 33: 569-73.
- 14 Dalabih A, Pietsch J, Jabs K, et al. Extracorporeal membrane oxygenation as a platform for recovery: a case report of a child with pulmonary hemorrhage, refractory hypoxemic respiratory failure, and new onset Goodpasture syndrome. *J Extra Corpor Technol* 2012; 44: 75-7.
- 15 Hovland A, Hardersen R, Nielsen EW, et al. Hematologic and hemostatic changes induced by different columns during LDL apheresis. *J Clin Apher* 2010; 25: 239-300.
- 16 Linenberger ML, Price TH. Use of cellular and plasma apheresis in the critically ill patient: Part II: clinical indications and applications. *J Intensive Care Med* 2005; 20: 88-103.
- 17 Frías MÁ, Jaraba S, Ibarra I, et al. Ventricular assist device as a bridge to transplant, and extracorporeal membrane oxygenation for primary graft failure in a child with hemophilia A. *Pediatr Crit Care Med* 2011; 12: e432-5. □